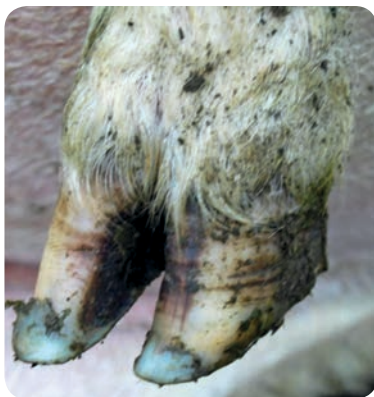


DIAGNOSIS & TREATMENT OF LAMENESS IN SHEEP





Disclaimer: QMS shall not in any event be liable for loss, damage or injury suffered directly or indirectly in relation to this guide or the research on which it is based.

General tips on foot care

1. Lameness is impossible to eliminate but it can be controlled
2. Regular foot inspection is important
3. In most cases, routine trimming of all feet is unnecessary and can actually do more harm than good
4. Correct diagnosis and early treatment improves the chances of success
5. Good handling facilities reduce stress on both the operator and the animal
6. Rough or dirty handling pens can cause hoof damage and spread foot infections
7. Always record or mark treated animals (you can use the notes at the end of this booklet). If lameness persists, repeat treatments after 14 days
8. If a third treatment is required, consider culling the persistent offenders
9. Seek veterinary advice if necessary

The healthy hoof – know what is “normal”

Knowing how a healthy foot should look will make it easier to recognise abnormalities and disease.

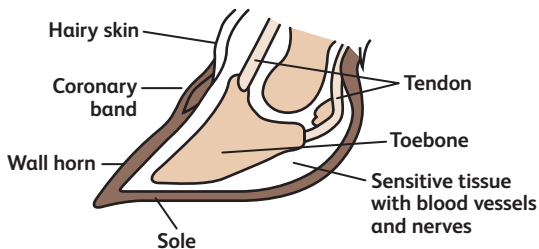
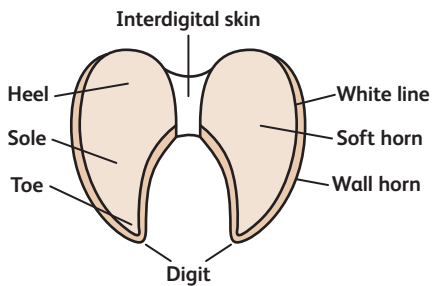
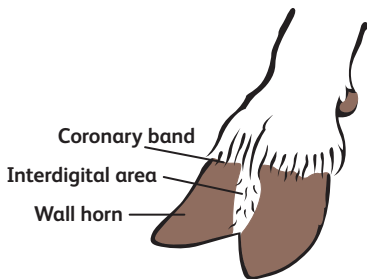
A normal foot has a hard wall of horn around two claws, each with a softer sole horn at the base. In healthy sheep, the interdigital skin between the claws is pale pink, dry, with a layer of fine hairs.

The sole horn is only 2-3mm thick and easily damaged by thorns or other sharp objects. The wall horn bears the sheep's weight, so a normal foot has wall horn that extends beyond the sole.

In a healthy foot, the horn of both sole and wall is intact without smell, heat, softness or separated horn. If a sheep is not lame and its feet are of normal shape (see pictures opposite), leave well alone.

Wall horn grows at the rate of about 5mm a month and the length of sheep feet varies naturally over the seasons. Over a year growth often matches wear so trimming is not necessary.

On some occasions the wall horn curls over the sole horn. This does not usually cause harm so foot trimming is unnecessary, unless the hoof horn is severely overgrown and the sheep is lame.



(Image kindly supplied by EBLEX BRP)

Scald

(interdigital dermatitis)

Signs:

- Claws are healthy but the interdigital skin is inflamed and swollen, often covered by a thin layer of grey/white material
- Lameness is usually mild

Cause:

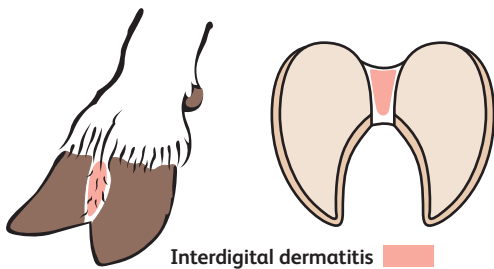
- Infection by *Dichelobacter nodosus* through damaged skin

Treatment:

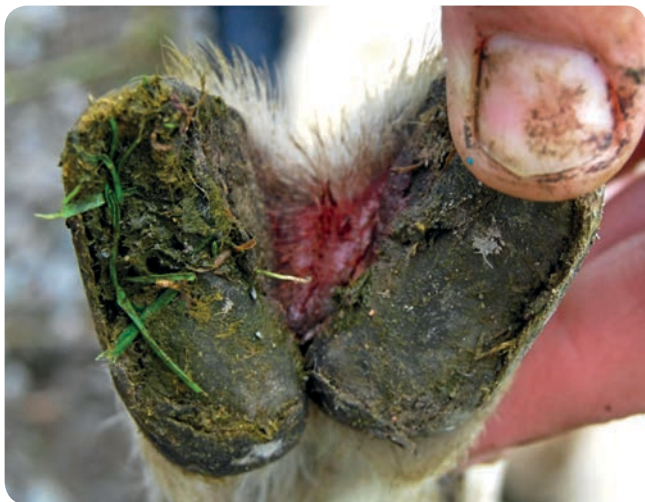- Antibiotic sprays to affected individuals, on clean and dry hoof
- Foot bath the entire flock following an outbreak, and repeat regularly, especially during high risk periods (warm, wet weather) and when conditions may lead to softening or irritation of the feet (e.g. during housing, grazing rocky areas or cereal stubble)

Prevention:

- Controlling foot rot in ewes helps reduce scald levels in lambs
- Minimize irritation of the skin between the claws by:
 - Keeping sward height low especially during June and July
 - Cutting stemmy swards for hay or silage
 - Removing thorns, hedge trimmings, etc. from fields
- Keep feet as dry as possible by:
 - Ensuring pens are dry and well bedded
 - Moving troughs regularly to prevent heavy poaching
- Avoid high stocking densities in pens and at pasture
- Applying builders' lime around troughs and gateways may help to reduce the infection



(Image kindly supplied by EBLEX BRP)



Foot rot

Signs:

- Separation of the horn from the foot (severe infections may cause the entire horn capsule to become detached)
- Affected sheep will usually be quite lame
- Infected tissue under the loose horn becomes a grey, oozing pus with a distinctive foul smell

Cause:

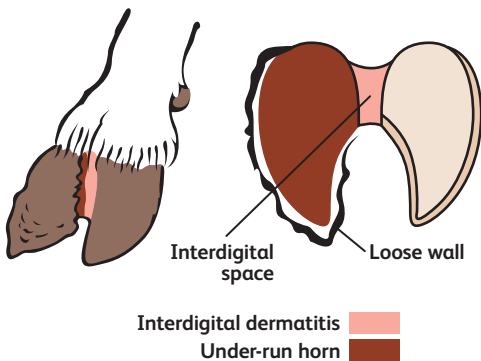
- Footrot, like scald, is caused by *Dichelobacter nodosus*
- From the initial scald, the infection moves down the heel then outwards along the sole
- Severe infections can extend to the outer wall of the hoof

Treatment:

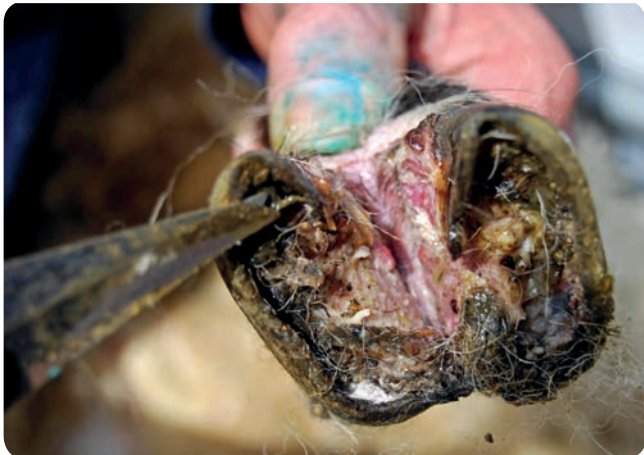- Investigate suspected foot rot cases as soon as possible
- Antibiotic spray on clean and dry hoof, combined with a long-acting antibiotic injection (take advice from your vet)
- Do not foot trim: it would delay healing and trimmings remain infected for several weeks. The overgrown horn will wear away

Prevention:

- Mark infected animals and ideally isolate in a separate field or pen to reduce the risk of infecting healthy feet
- Cull animals requiring more than 2 treatments in a season
- Avoid buying in sheep with foot rot
- Quarantine bought in animals and footbath at least twice before mixing with the rest of the flock
- Vaccinate prior to high risk periods (protection is short lived)



(Image kindly supplied by EBLEX BRP)



Shelly hoof

Signs:

- Sole horn separates from the wall horn forming an air pocket
- The severity of shelly hoof can vary from small, discreet lesions to loss of the hoof wall
- In many cases sheep will show no signs of lameness
- The air pocket can become filled with soil, stones, etc leading to physical discomfort, secondary infections and clinical lameness
- Secondary infections are easily misdiagnosed as foot rot

Cause:

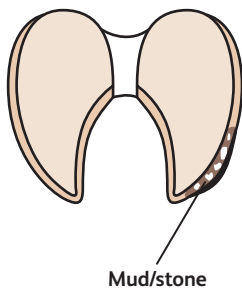
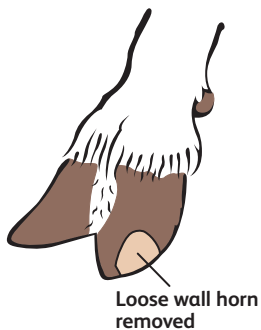- The exact cause is presently unknown. There are suggestions it is associated with the following:
 - damage from rough, wet or stony ground
 - a nutritional deficiency or imbalance
 - certain breeds or strains of sheep

Treatment:

- The objective is to avoid impacting the air pocket
- Carefully trim the horn to remove the loose horn and treat with an antibiotic spray if there is infection
- If the air pocket is clean and not infected, consider filling the hole with hoof putty

Prevention:

- There is currently no proven method of prevention
- If there is a high level of shelly hoof it may be good practice to check nutritional status of the flock and correct any mineral or vitamin imbalances in the diet



(Image kindly supplied by EBLEX BRP)



White line (toe) abscesses

Signs:

- Sheep will become very lame, often very suddenly
- The infected hoof is often swollen and may be hot to touch
- If severe, pus can burst out at the top of the hoof (coronary band) or along the heel. The pus often has a strong smell

Cause:

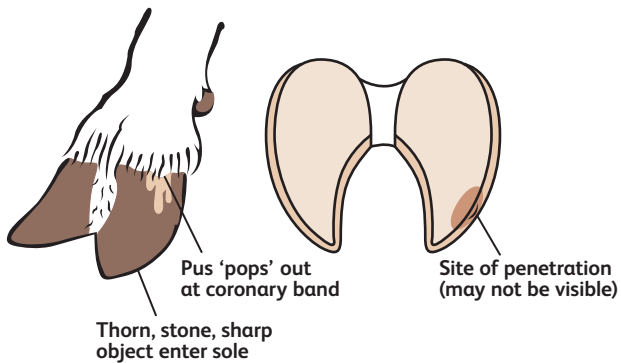
- Infection usually follows puncturing of the hoof (by thorns, stones, etc), and in some cases, shelly hoof. The abscess then tracks rapidly upwards underneath the wall horn

Treatment:

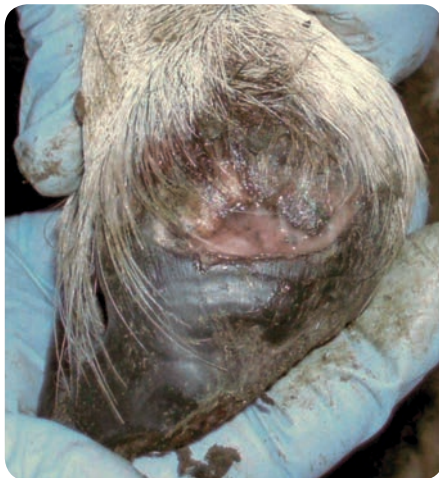- Trim the sole below the site of the abscess, just enough to drain the abscess and release pressure. If the abscess has already burst, do not trim horn
- Once pus is draining, treat with an antibiotic injection and spray
- Sheep generally recover after the pus bursts out, although it can take up to 6 weeks for new horn to grow back
- Animals with a permanent horn defect can be repeatedly affected. Consult your vet if signs persist

Prevention:

- Reduce the risk of foot damage by:
 - Removing thistles, thorns, hedge trimmings, etc. from pasture
 - Ensuring roadways and tracks are well maintained
 - Ensuring housing and handling facilities are well maintained



(Image kindly supplied by EBLEX BRP)



Toe Granuloma (strawberry)

Signs:

- A strawberry-like growth (proud flesh) develops on the foot, usually around the toe
- The strawberry often bleeds when touched
- The condition is very painful and sheep may not bear weight on the foot

Cause:

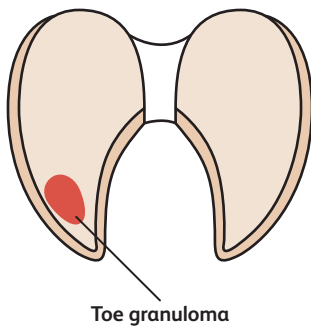
- Most commonly due to excessive foot trimming, with the sensitive living tissue under the horn growing proud of the horny capsule
- It can also follow untreated cases of severe foot rot or puncture wounds

Treatment:

- Consult your vet (anti-inflammatory drugs can help control the pain)
- The condition will rarely heal properly so consider culling
- Attempted removal will cause heavy bleeding and the lesion will most likely grow again

Prevention:

- Avoid excessive foot trimming (i.e. avoid bleeding when trimming hoof horn)



(Image kindly supplied by EBLEX BRP)



Pedal joint (foot) abscess

Signs:

- The affected claw becomes badly swollen and extremely painful
- Pus can burst out of the hoof in several places, including between the claws, and often with hair loss above the hoof
- Signs are often seen in fat, heavy sheep, and particularly common in heavy rams

Cause:

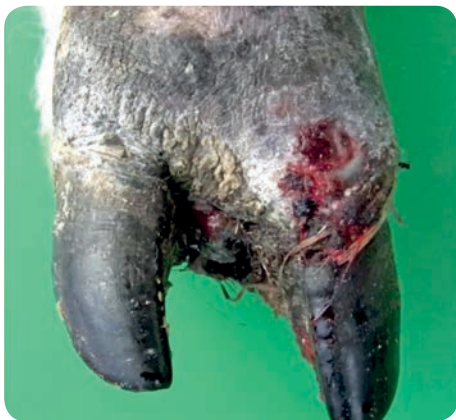- Infection is caused by bacteria commonly found in the gut and faeces of healthy sheep. Bacteria enter the foot through damaged skin
- Infection leads to abscess formation in the deeper foot tissues

Treatment:

- Antibiotic treatment will be unsuccessful once the joint within the hoof is severely and permanently damaged
- Seek veterinary advice as claw amputation may be necessary
- Even with amputation the animal may never fully recover, so consider culling

Prevention:

- Avoid predisposing causes of abscess such as over fatness, wet or muddy ground conditions
- Ensure handling pens and bedding materials are as clean and dry as possible to minimise contact with faeces



Contagious ovine digital dermatitis (Codd)

Signs:

- The infection starts as small ulcers at the coronary band but rapidly moves down the claw, undermining the horn
- Usually some hair loss is seen above the coronary band
- The entire horn capsule may become detached
- Infected tissue has a grey, pasty scum-like appearance with some blood staining but no significant smell

Cause:

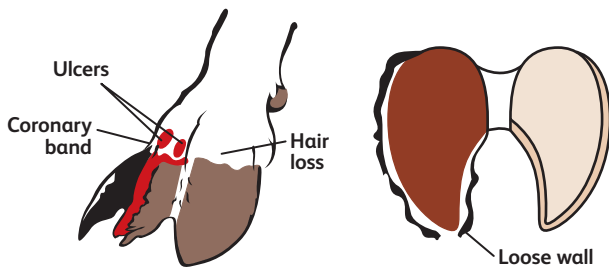
- Thought to be caused by spirochaete bacteria, similar to digital dermatitis in cattle

Treatment:

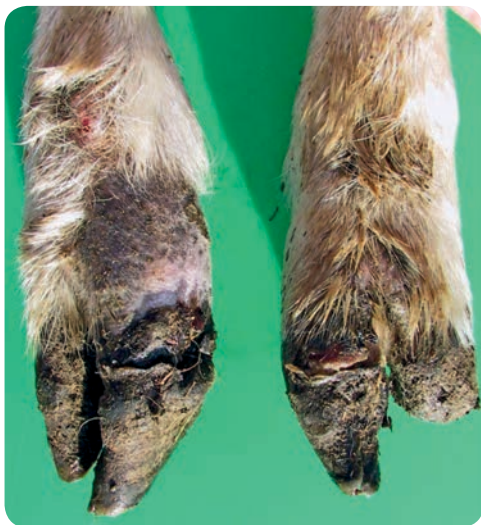- Do not trim. The hoof horn, although loose, still protects the living tissue underneath
- Antibiotic footbaths, injections and sprays are not always effective. Consult your vet for the latest recommendations
- Culling of severely affected sheep may be necessary on welfare grounds

Prevention:

- Avoid buying in sheep from flocks with Codd. Quarantine for as long as possible, cases often arise several months after purchase
- Avoid mixed grazing if digital dermatitis is present in cattle
- Isolate suspected cases and seek veterinary advice immediately. This will help to minimize disease spread and reduce the risk of permanent foot damage



(Image kindly supplied by EBLEX BRP)



Joint ill

Signs:

- Lambs 5-10 days old suddenly become lame
- Feet appear healthy
- Leg joints are swollen, hot and extremely painful
- Multiple joint infections in the same animal are common

Cause:

- *Streptococcus dysgalactiae* (and sometimes other bacteria) infections acquired during the first few days of life
- Bacteria enters via the gut, respiratory tract, tonsil or navel

Treatment:

- Antibiotic injection given once daily for 5 consecutive day
- Treatments given during the early stages of infection are most successful, although signs of lameness may persist if the joint has been damaged
- If an epidemic is occurring, seek further veterinary advice

Prevention:

- Ensure lambs consume adequate colostrum (150 ml/kg) in the first day of life
- Maintain high standards of hygiene around lambing:
 - Ensure lambing areas are clean, dry and well-bedded
 - Clean and disinfect individual lambing pens between ewes
 - Immerse navels in veterinary iodine solution within 15 minutes of birth and repeat 2-4 hours later
 - Turn ewes and lambs out to pasture as soon as possible



The animal on the left is affected by joint ill

Soil balling

Signs:

- Hard lumps of soil, mud, faeces or bedding material gather between the claws causing irritation
- Might lead to scald, foot rot or other foot conditions if left untreated

Cause:

- In moist conditions, soil, mud, faeces or bedding material gathers between the claws
- Material dries out forming hard lumps which stick to the claws

Treatment:

- Run the flock along a concrete/tarred road to loosen and break off soil
- Walk sheep through a water bath (or foot bath) to soften the lump
- Manually remove the encrusted material from affected sheep and spray with an antibiotic spray if the skin is raw

Prevention:

- Keep bedding material as clean and dry as possible
- Avoid puddling around feed troughs during wet weather
- Provide a grass or stubble run-back for sheep grazing roots or forage crops

[illegible]

Skin growths (interdigital hyperplasia, fibromas, corns)

Signs:

- Growths develop on the skin between the claws causing irritation
- Lameness is usually mild, but large growths are painful and can become traumatised, leading to scald or foot rot

Cause:

- The exact cause is unknown but is most likely heritable
- The condition may also follow chronic irritation or scald, or both

Treatment:

- Treat scald and foot rot infections promptly and appropriately
- Contact your vet: surgical removal may be successful if detected early
- Once growths are enlarged and cause lameness they tend to recur

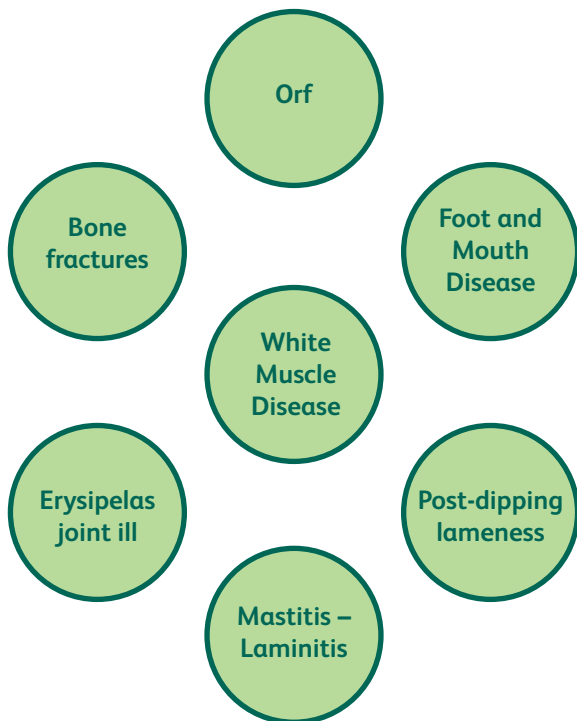
Prevention:

- Avoid breeding from affected animal
- Ensure good control of scald in the flock

[illegible]

Other causes of lameness in sheep

Consult your vet if you suspect lameness may be due to any of the following:





Foot bathing best practice

1. Before foot bathing, check that equipment and handling pens are in good condition
2. Foot bathing is best carried out on a dry day
3. If possible, try to have feet as clean as possible before foot bathing. This is most easily achieved by placing a second foot bath, filled with water, immediately before the main treatment foot bath
4. Use solutions at concentrations recommended by the manufacturer. High concentrations of some foot bathing products will damage the feet and skin, making the problem worse
5. Make sure the foot bath solution is deep enough to cover the entire hoof and that all feet are treated
6. Allow animals to stand in the footbath solution for the recommended time. This is more easily achieved with stand-in pens rather than walk-through baths
7. For best results, allow the sheep to stand on a hard dry surface for up to one hour after treatment
8. After foot bathing, move the sheep onto dry pasture which has not been grazed within the previous 2 weeks
9. Dispose of the footbath solution carefully



Footbathing solutions

Zinc sulphate

The usual recommended strength is 10% when using zinc sulphate hexahydrate (1kg powder per 10L water), or 6.5% when using zinc sulphate monohydrate (650g powder per 10L water)

Pros

- Remains effective after contamination with soil, faeces, etc
- Gentle on feet and skin

Cons

- Difficult to dispose of since it is a heavy metal
- Usually requires a stand time of at least 5 minutes

Copper sulphate (blue stone)

The usual recommended strength is 5% (500g powder per 10L water)

Pros

- Better penetration of the foot than zinc, therefore requiring shorter stand in time

Cons

- Toxic to sheep and wildlife (its use is restricted or banned in some countries)
- Can lead to copper poisoning
- Difficult to dispose of since it is a heavy metal
- Reacts with galvanised metal equipment



After foot bathing or after treating infected hoofs with antibiotic sprays, the animals should stand on a hard, clean and dry surface to maximise treatment efficacy

Formalin

For prevention of scald it is best used at 2-3% concentration (200-300ml of 40% formaldehyde solution per 10L water)

Pros

- Requires a very short stand time so the best option for walk-through footbaths, provided sheep move through steadily
- Disposal of the solution carries less environmental risks than most other products

Cons

- The risk of skin damage is increased at concentrations above 3%
- May cause excessive hardening of the horn if used frequently
- Formalin is both toxic and carcinogenic. It should not be used in confined spaces and must be handled with care. Use of formalin for footbathing is prohibited in some countries
- Very painful to animals (and humans) with open wounds

Commercial solutions

Commercial products should be diluted and used as per the manufacturer's instructions. Check for claims of efficacy and/or if the product is formally licensed.

Antibiotic footbaths

Antibiotic preparations are not currently licensed for use in footbaths, but they may be necessary to treat CODD. Consult your vet before use.



Foot trimming best practice

1. Foot trimming should only be carried out to:
 - a. Help diagnose a problem with diseased feet, if scald, foot rot or CODD are not present in any of the four feet
 - b. Re-shape badly overgrown feet
 - c. Remove loose horn (in case of shelly hoof)
2. Ensure the foot shears or knife is sharp and regularly replaced
3. Clean and disinfect the foot shears regularly (ideally after each foot), for example, by dipping in 10% zinc sulphate solution
4. Wear disposable gloves to reduce spread of infection. When routinely inspecting feet, always inspect lame sheep last
5. Ensure feet are clean before trimming
6. With the animal properly restrained:
 - a. Leave 2-3 mm wall horn overhanging the sole around the claw, to give protection to the sole when weight bearing
 - b. From the toe, trim the outer wall, working backwards
 - c. From the toe, trim the inside wall of each claw, working backwards
 - d. Make as few cuts as possible
7. Avoid over-trimming and do not draw blood
8. Turn sheep out to pasture that has not been grazed by sheep in the past 2 weeks
9. Collect and burn all hoof trimmings, clean and disinfect the treatment area after use

This guide was compiled and edited by:

Dr Ronald Annett, AFBI

Dr Marijntje Speijers, AFBI

Dr Aurélie Aubry, AFBI

With major contributions from:

AgriSearch

Prof Laura Green, University of Warwick

Prof Agnes Winter, University of Liverpool

Dr Jason Barley, AFBI

Photography:

AFBI

Agnes Winter (cover picture)

University of Warwick (white line abscess)

Philip Scott (Pedal Joint abscess, CODD, joint ill)

For more information please contact:

Quality Meat Scotland

The Rural Centre,

Ingliston,

Newbridge,

EH28 8NZ

T: 0131 472 4040

E: info@qmscotland.co.uk

www.qmscotland.co.uk



Quality Meat Scotland

The Rural Centre, Ingliston, Newbridge, EH28 8NZ

T: 0131 472 4040 **E:** info@qmscotland.co.uk **www.qmscotland.co.uk**